

# Characterization of Infected Diabetic Wound after Ozonated Water Therapy

Vipavee Anupunpisit<sup>1</sup>, Suwadee Chuanchaiyakul<sup>1</sup>, Hattaya Petchpiboolthai<sup>1</sup>,  
Sumon Jungudomjaroen<sup>1</sup> and Waigoon Stapanavatr<sup>2</sup>

<sup>1</sup> Department of Anatomy, Faculty of Medicine, Srinakharinwirot University, Sukhumvit 23, Bangkok 10110, Thailand <sup>2</sup> Department of Surgery, Bangkok Metropolitan Administration and Vajira Hospital, Bangkok 10300, Thailand

---

## ABSTRACT

The efficiency of ozonated water therapy in infected diabetic wound, emphasizing on structural characteristics was studied. The ozonated and non-ozonated skin wounds, emphasizing in epidermis and dermis, were compared and analyzed by light and transmission electron microscopes. The microbicidal efficacy of ozone against pathogenic infection of skin was recognized. After five-day interval of ozone exposure, the ozone treated wounds demonstrated the well-defined characteristics of cell and tissue regeneration, worthy skin replacement, and regeneration of healthy epidermal cells. Consequently, the improvement of dermis was demonstrated by well-defined reformation of newly formed fibroblasts and organized collagen fibers. The majority of defensive cells were lymphocytes and migrating plasma cells, together with clarifying foreign body giant cell. On the contrary, the first-day untreated wounds demonstrated the bacterial infection in destroyed epidermis, and deformation of fibroblast and collagen fibers respectively. The spreading distinct abscess areas were demonstrated by great migration of white blood cells, especially neutrophils and lymphocytes inside the blood vessels and connective tissue. With reference to the fifth-day untreated wound, the areas of damaged epidermis were recognized, including severe abscess, increased numbers of white blood cells, and inflammation of blood vessels with microthrombus. In summary, ozonated water therapy should be applied as alternative medicine in order to improve the reconstruction and healing of infected diabetic wound. Particularly, the significant impact will be beneficial for social and economy of the country, as well as physical and mental health of patients.

**keywords :** diabetic wound / ozonated water therapy / light microscope (LM) / transmission electron microscope (TEM) / epidermis / dermis / abscess

### Corresponding author :

Asst. Prof. Vipavee Anupunpisit

E-mail : vanupunp@swu.ac.th

## INTRODUCTION

At present, the role of ozone ( $O_3$ ) still remains controversial, with the potential for harmful and beneficial effects. Actually, ozone is a natural gas that distributes approximately 0.01-0.04 ppm (part per million) of world atmosphere. It is an unstable gas, which will be breakable to be oxygen gas ( $O_2$ ) and oxygen atom (O). Oxygen atom, being a strong oxidizer, appears to be a good agent for sterilization by oxidation process; therefore, the strong oxidizing activity of ozone becomes very useful for the inactivation and destruction of bacteria, fungi and viruses. The effectiveness of ozone against pathogens was well recognized in the cell death and lysis of microorganisms (1-3). Therefore, ozone has been successfully applied and commercially used in decontamination of microorganisms in bio-clean rooms (4), food preservation (5-7) and drinking water (8-9).

Owing to the application of ozone in medical treatments, ozone therapy has revealed a benefit on blood lipid metabolism and provoked the activation of antioxidant protection system in patients with myocardial infarction (10). Clinical practice has used oxygen-ozone therapy in the treatment of peripheral occlusive arterial disease (11) and dental caries (12). Moreover, ozone exposure has shown the profound effects on immune function (13), reducing influenza disease severity (14), modulation of mast cell function (15), and well split-thickness skin grafts (16). However, the toxicity effects against plant, animal cells have been revealed in long term or chronic exposure (17). The efficiency of ozone exposure would depend on many factors, such as ozone concentration, duration of exposure, environmental factors, etc. Therefore, the appropriate and controllable amount of ozone should be used to display biological effects and therapeutic application.

Consequently, the aim of this study is to elucidate the structural changes and improvement of cells and tissues of the infected diabetic wound after the external ozone treatments. We also observed the effect of ozonated water therapy on the process of microbicidal activity. Structural characterization of cells and tissues in epidermis and dermis layers of skins were determined and compared using light and transmission electron microscopes.

## MATERIALS AND METHODS

*Ozone Treated and Non-ozone Treated Wound Samples of Skin.* Diabetic mellitus patients from Vajira hospital, with diabetic foot infection, were participated and separated into two groups, ozone treated and non-ozone treated groups. The laboratory procedures used in this study were described by Stapanavatr et al., 2001 (18). The patients were admitted according to indication of admission as followings: dry gangrene, nonheal ulcer, rest pain, infection of lesion, with surrounding cellulitis, gross pus or necrotic tissue. The infected skin tissues were collected and the microorganism were cultured and identified from the medical laboratories. All patients would be investigated, diagnosed and treated according to the standard clinical treatment by the medical physicians. The control non-ozonated group was admired by sterilized water therapy whereas the ozonated group was dressed by external ozonated water therapy for 15 min once a day before antiseptic wound cleanings and dressings. Clinician staff performed the surgical debridement on the first and fifth day after treatments of both groups. The experimental nature of the study was explained to the patients and followed the rule of Bangkok Metropolitan Administration and Vajira Hospital.

*Ozone Method.* Ozone was generated from commercial ozone generator (Brightzone) model OZ-100 (Bright-gren Technology Co. Ltd., Hsin-Tien City, Taiwan) by using atmosphere air as the oxygen source. The ozonated air produced at a constant high flow rate by the apparatus was passed by a silicone tube to a diffuser. The concentration of ozone used was 40 mg/h with the fixed volume of the treated solution (4 litres) or equivalent to 0.167 mg/min/litre.

*Light Microscopic Study.* The collected skin tissues were fixed in neutral buffered formalin-fixative solution for at least 24 h, then dehydrated in increasing concentration of ethanol (from 70%, 80%, 90%, 95% to absolute isopropyl alcohol) for two times, 10 min/time. The clearance xylene was applied twice, with an interval of 30 min, then the paraplast plus was used for routine tissue embedding. The tissue was sequentially sectioned for 8-micron thickness, using microtome (Reichert-Jung, Cambridge Instruments GmbH Mod. 2040 Autocut, West Germany), followed by conventional mayer hematoxylin & eosin staining. The tissue sections were preserved by permount solution. The

identified tissues were analyzed and photographed by light microscope (Olympus BX 50F, Olympus Optical Co. Ltd, Japan).

**Transmission Electron Microscopic Study.** The collected skin tissues were fixed sequentially in three fixatives; firstly, in ice-cold 2.5% glutaraldehyde in 0.1 M sodium cacodylate buffer, pH 7.4, for 2 h and followed by three washes with the same buffer. Secondly, the specimens were fixed in 1% osmium tetroxide in 0.1 M sodium cacodylate for 2 h at 4° C, and washed three times with distilled water. Finally, 1% uranyl acetate was used for 0.5 h followed by washing three times with distilled water. They were then dehydrated in increasing concentration of ethanol (from 50%, 70%, 80%, 90%, 95% to absolute alcohol). The infiltration process was performed by using the mixture of propylene oxide and epoxy resin at the dilution of 2:1 for 1.5 h and 1:2 for overnight respectively. Then, the samples were proceeded in polymerization and embedding processes in pure epoxy resin, incubating at room temperature for 1 day, at 45° C for 2 days and at 60° C for 3 days respectively. Ultrathin sections of 100 nm/section on copper grids were performed by using ultramicrotome (MT-700, RMC Microtomy and Cryobiology Products, USA), stained with 4% uranyl acetate and 1% lead citrate for 5 min per each application. The specimens were examined and photographed by the JEOL, JSM-1200 EXII transmission electron microscope (Electron Microscope JEOL LTD, Tokyo, Japan) operating between 40-120 kV.

## RESULTS

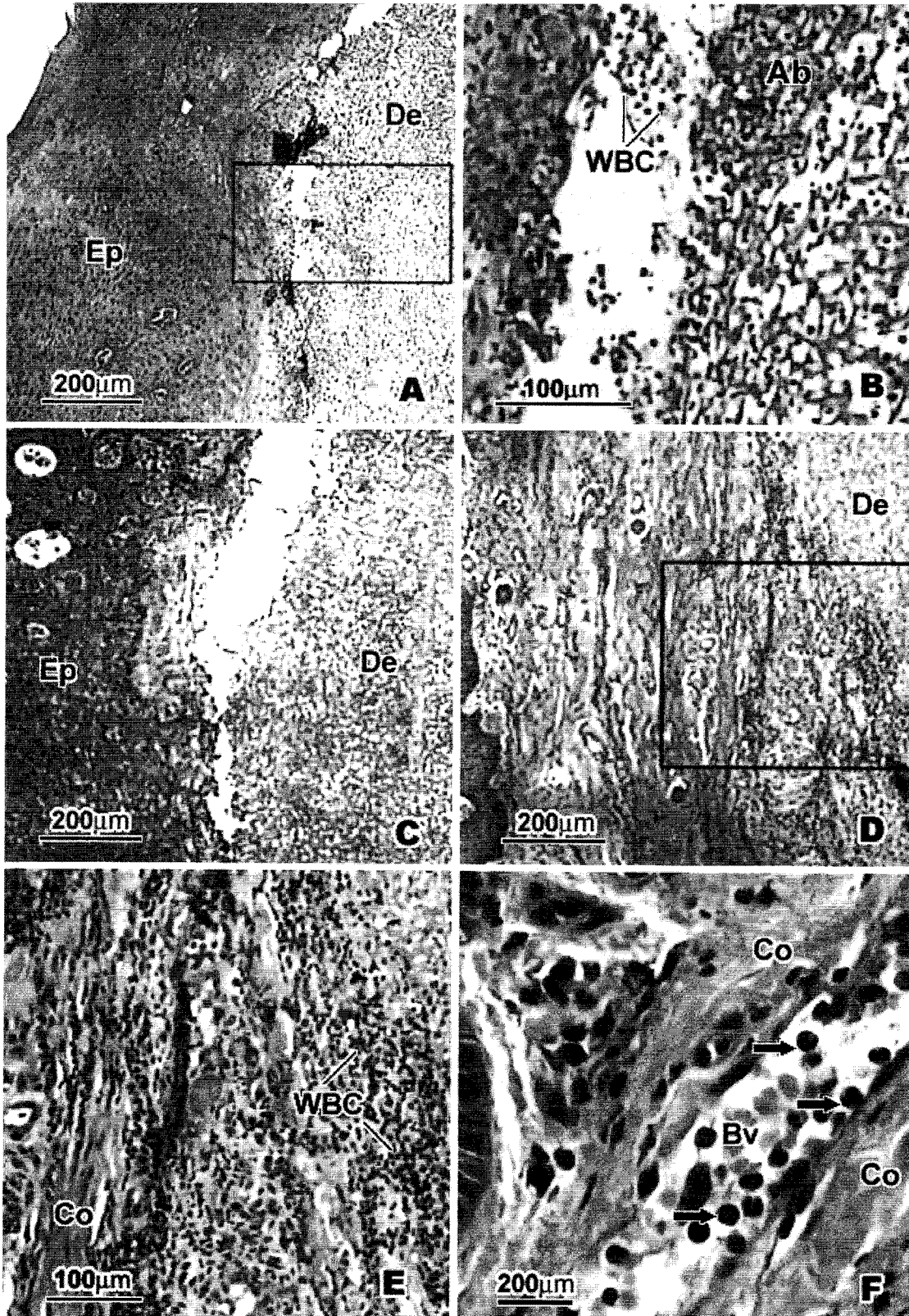
To study the efficacy of ozonated water therapy in infected diabetic wound, we investigated the lesions and healing characteristics of cells and tissues of skin, particularly in dermis and epidermis by using both LM and TEM. In order to elucidate the comparative structural characteristics, both LM (Fig. 1,3,5) and TEM (Fig. 2,4,6) results would be concurrently presented.

### *Characterization of Non-ozone Treated Skin of Infected Diabetic Wound*

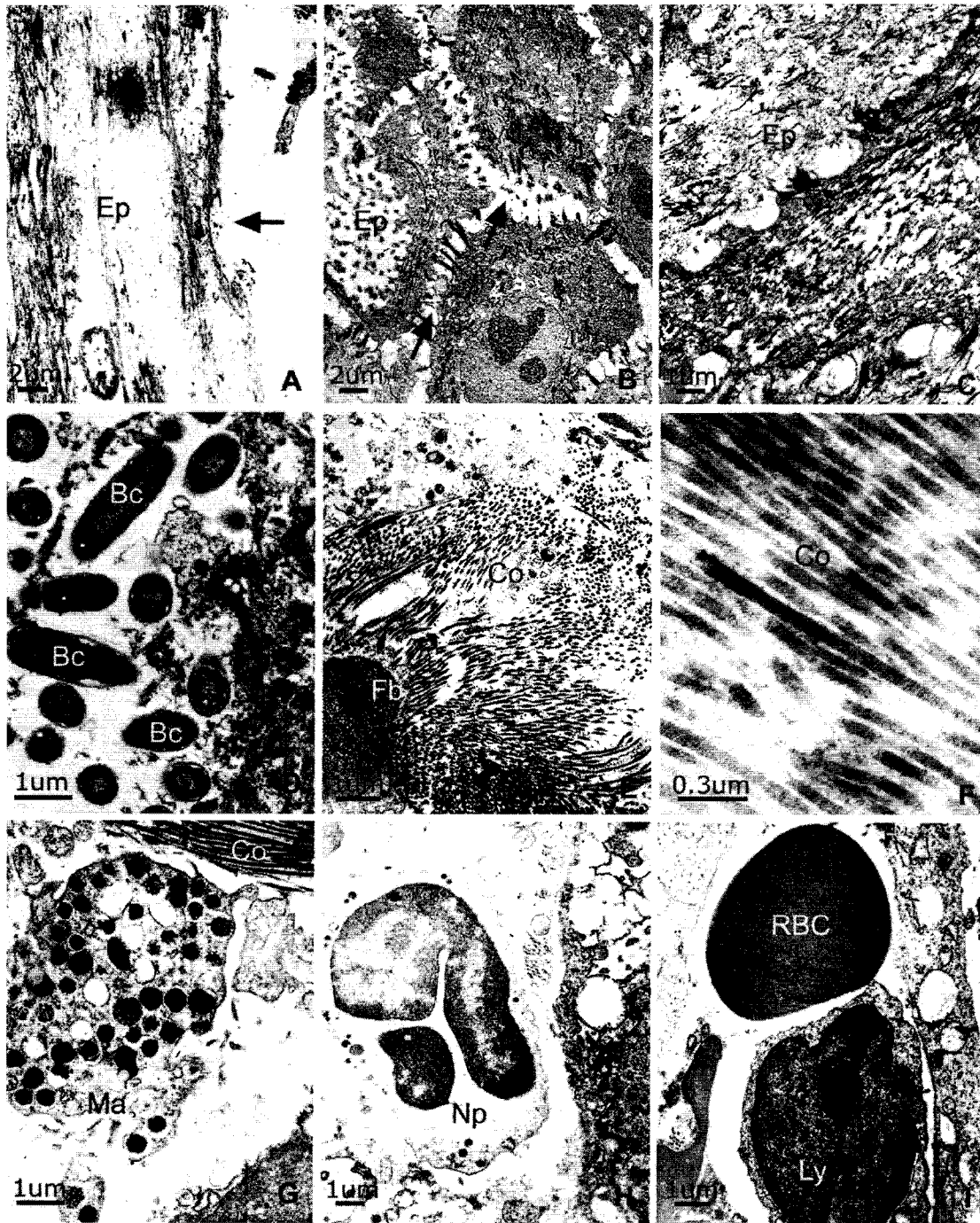
The non-ozone treated wound skin of the first-day samples showed that the whole layer of epidermis was destroyed and infected with bacteria (Fig. 1A-C; 2A-D). Outer keratin layer was totally absence. Uppermost flatten epidermal cell showed rupture and destroyed patterns (Fig.2A) whereas the lower

epidermal cells revealed degeneration signs, including ruptured cell membrane, swollen cell with vacuolization, cell lysis, and deformity of desmosome (intercellular bridges) (Fig. 2B). Epidermal cells extremely demonstrated pathological degeneration, with abnormal characteristic of embedding white blood cells including neutrophils and lymphocytes (Fig. 1A-C). In dermis, the fibroblasts show deformation and mild damage, together with the irregular deformation of collagen fibers and degenerated fibroblast (Fig. 2E-F). The distinct pathological disorder was the wide spreading area of abscesses which were presented as a huge cluster of neutrophils, red blood cells, secretion, and related structures. Correspondingly, the defense mechanism of the immunity system was expressed by the great migration of white blood cells, especially neutrophils and lymphocytes inside blood vessels (Fig. 1D-E; 2H-I) and through the connective tissue of dermis layer (Fig. 1F). Moreover, mast cells, which are related to macrophage relation, were also observed in the dermis area (Fig. 2G).

The fifth-day non-ozone treated wound showed major destruction and deterioration of epidermis significantly (Fig. 3A). Architectures of epidermal layer were totally unorganized and destroyed, together with an invasion of a large number of neutrophils. The loosen epidermal cells became large, swollen and desegregated throughout the area (Fig. 3B), co-incidentally with TEM level of smashed nucleus and cytoplasm and loosen separated intercellular bridges (Fig. 4A-B). Particularly, severe collapsed epidermal cell was observed as a dark smashed ring without nucleus (Fig. 4D). In dermis, the areas of abscess was severely spreading and distributing all over the wound areas with the increasing numbers of red blood cells, neutrophils, and lymphocytes, whereas incoming plasma cells initially appeared and aggregated as a cluster nearby the wound area (Fig. 3C-D; 4C, E-F). Irregularly deformations of fragmented collagen fibers and damaged fibroblast, including with embedding neutrophils, were obviously observed (Fig. 3C&F; 4H). Fragmentation of degenerated collagen fibers was presented as patchy of pointed dense particles (Fig. 4I). The particular inflammation of blood vessels together with enclosed microthrombus was rigorously established (Fig. 3E; 4G). Dermal granulation tissue, defined by accumulating of destroyed old cell and tissues replaced by generation of new functional cell and tissue (Fig. 3G).

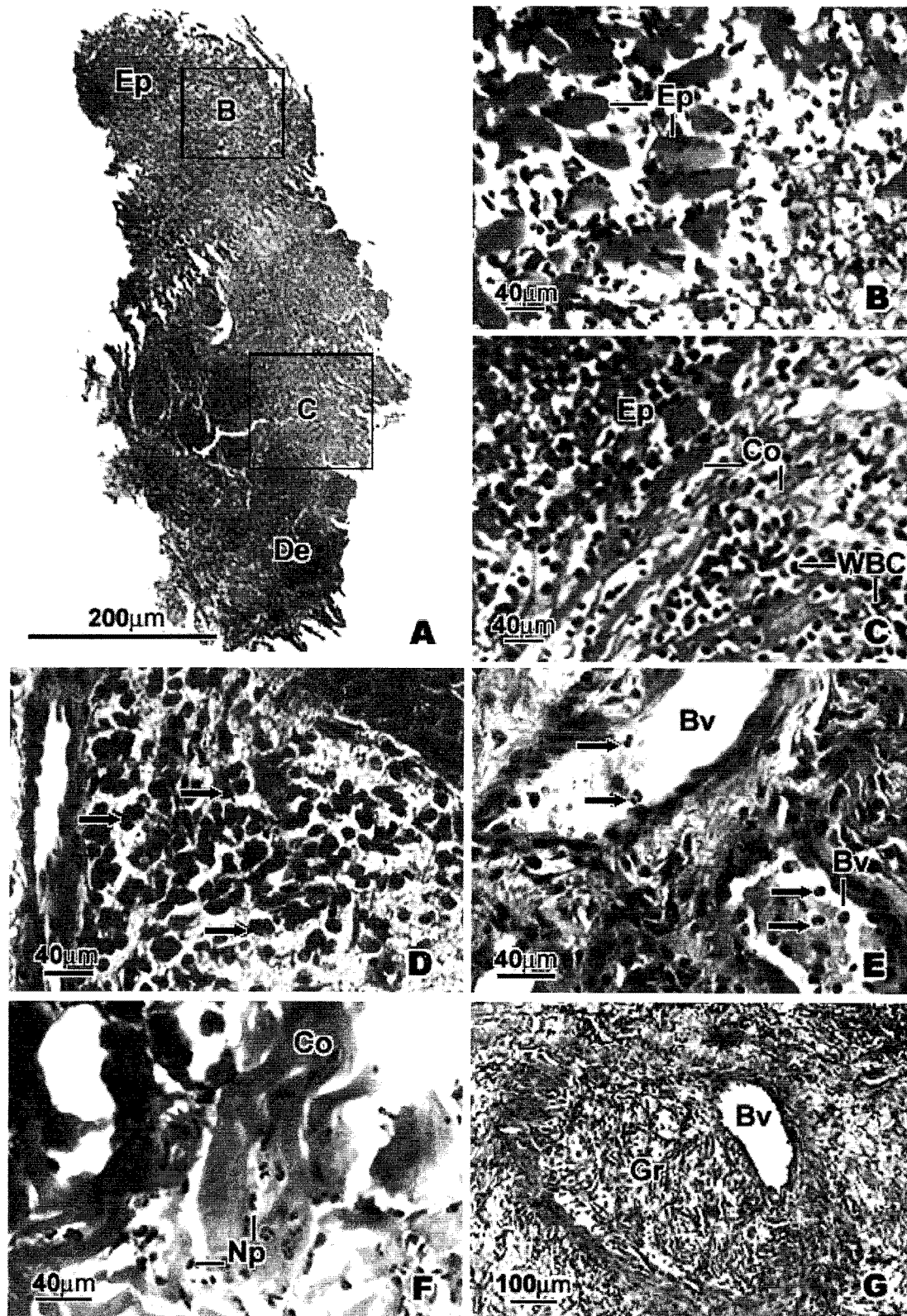


**Fig. 1.** Light micrograph of one-day infected wound in non-ozone treated skin. Inflammatory abscesses were localized in both epidermis (Ep) and dermis (De) (1A&C), demonstrating a large predominantly white blood cells (WBC): neutrophils in the abscess cavity (1B), magnified from the marked square area in 1A. In deeper dermis (1D-F), the expansion of acute abscess was enlarged (1E: the marked square area in 1D), revealing by lots of white blood cells, dispersed collagen fiber (Co), red blood cells and a large number of migrating neutrophils in the vessels (1F: arrows).

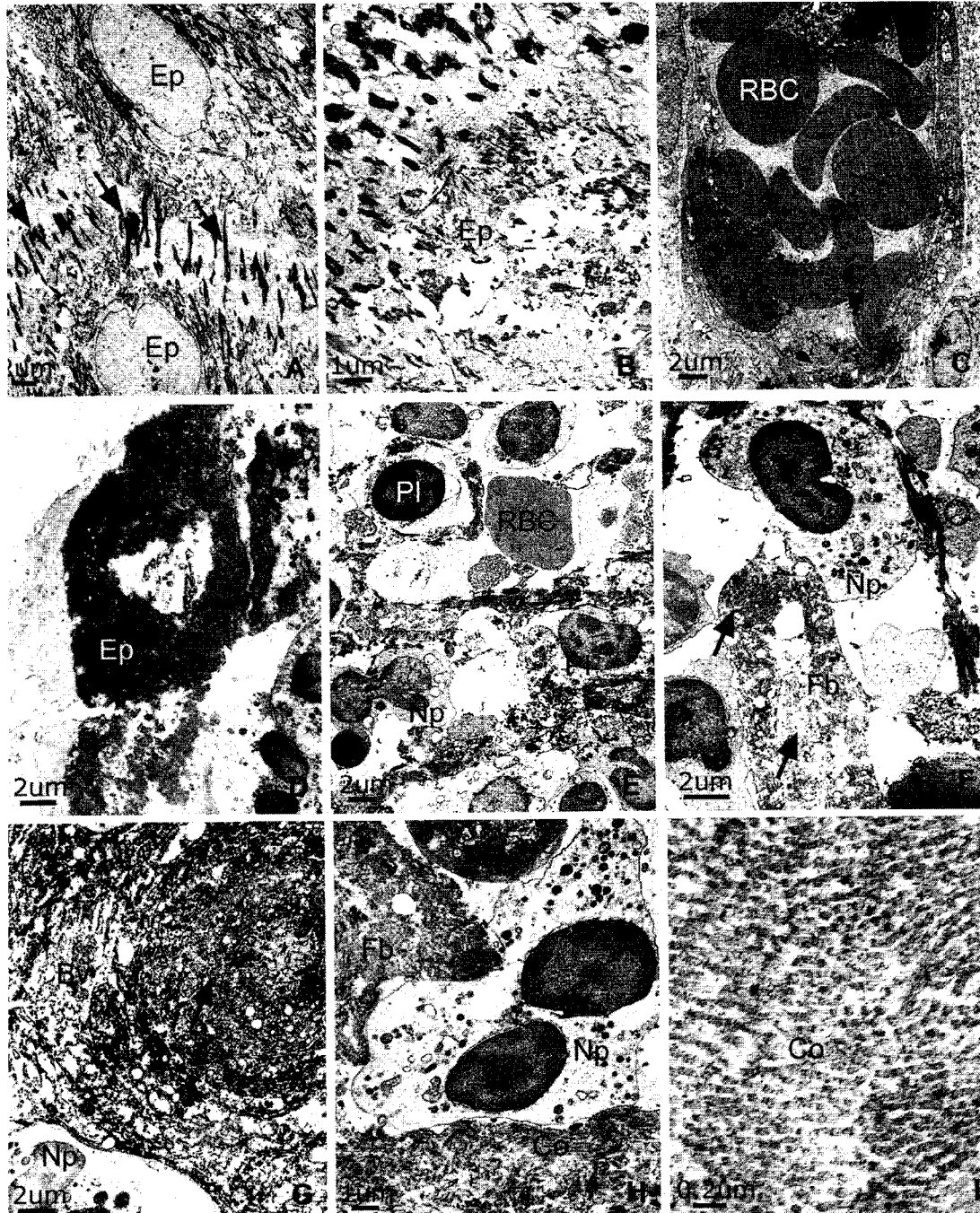


**Fig. 2.** TEM micrograph of one-day infected wound in ozone treated skin. Degenerated epidermis (2A-D) was revealed as ruptured epidermal cells (2A: arrow), deformity of intercellular bridges (2B:arrows), and infected bacteria (Bc). In dermis area (2E-I), the irregular deformation of collagen fibers (Co) and degenerated fibroblast (Fb) were presented together with red blood cell (RBC), macrophage (Ma), neutrophil (Np), and lymphocyte (Ly).





**Fig. 3.** Light micrograph of five-day infected wound in non-ozone treated skin. The severe lesion of epidermis (Ep) and dermis (De) were demonstrated (3A). Enlargement of marked B-square area of Fig. 3A showed the disorganization of swollen epidermal cell (3B), whereas enlargement of C-square area of Fig. 3A explored lots of white blood cells (WBC) and lyzed collagen fibers (Co) at the epidermo-dermal junction (3C). In deeper dermis, lots of inflammatory cells (arrows) were dominated in either tissue area (3D) or in blood vessels (3E: Bv), including dominant infiltrated neutrophils (3F: Np) between destroyed collagen fibers (Co). The presentation of granulation tissue (3G: Gr) was demonstrated together with blood vessel (Bv).



**Fig. 4.** TEM micrograph of five-day infected wound in ozone treated skin. Severe degeneration of epidermal cell (Ep) and disorganized of intercellular bridge (arrows) were shown in 4A-B. Severely collapsed epidermal cell was observed as a dark smashed ring without nucleus (4D). In dermis (4C, E-I), the abscess and inflammatory response were severely spreading with a lot of red blood cells (RBC), neutrophils (Np), lymphocytes (Ly), plasma cells (PI), microthombus (4G: arrow) in blood vessel (Bv) together with damaged fibroblast (Fb) and fragmented collagen fibers (Co).

### *Characterization of Ozone Treated Skin of Infected Diabetic Wound*

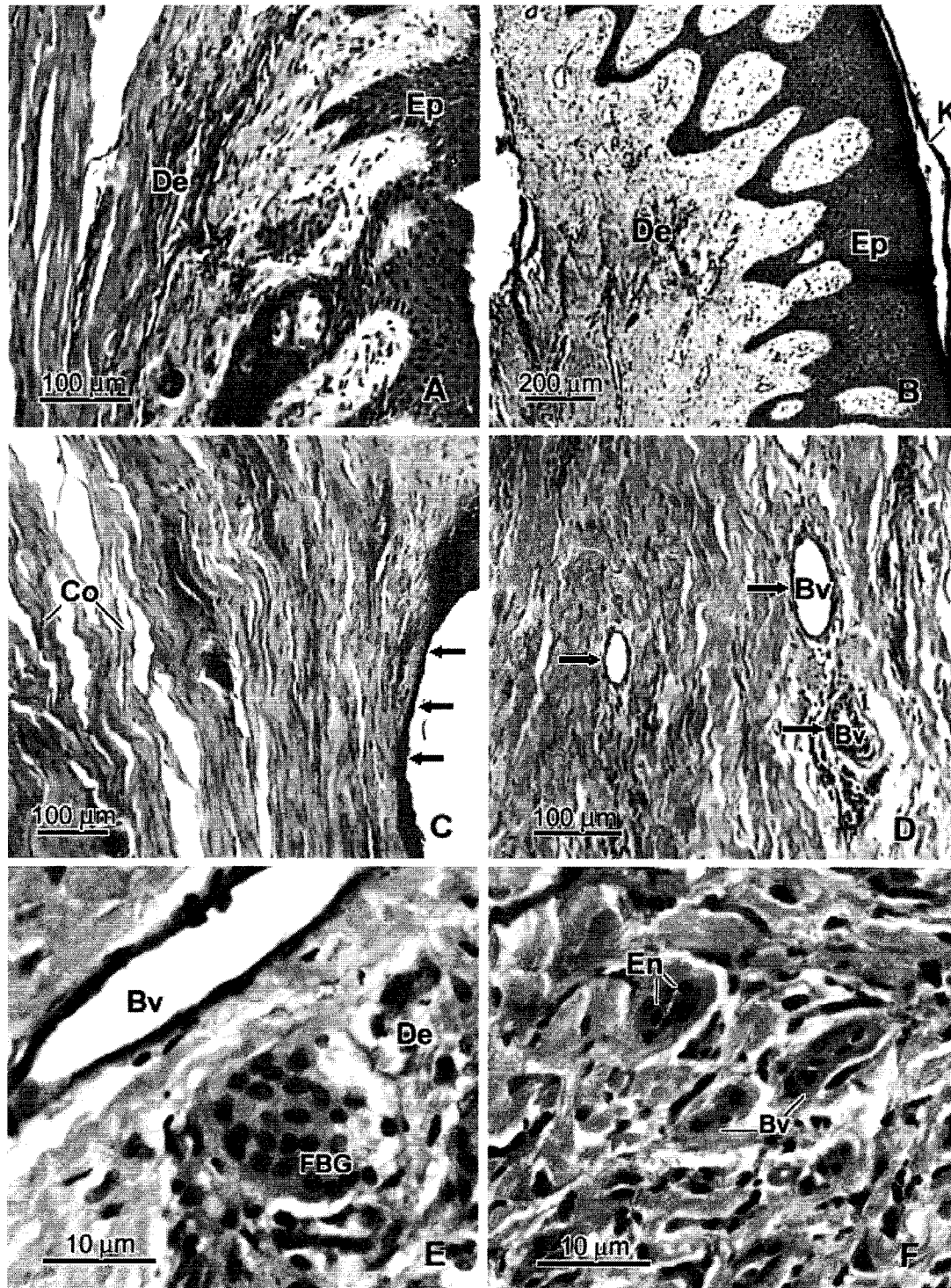
After five days of ozone treatment, the wound tissue showed the well-defined repair appearance, demonstrating in growth and development of healthy epidermal cells. At LM level, it has been clearly shown that a few layers of new simple squamous epithelial cell were regularly composed at wound areas, which has been totally smashed out (Fig.5C). TEM result confirmed that very organized arrangement of newly formed epidermal cells was reconstructed. These individual cells had a very large nucleus with prominent nucleolus, rich cytoplasm with related organelles, dark packed granules, and initiated-form intercellular bridges (Fig. 6A). Specifically, characteristic of cell division of epidermal cell has been demonstrated as metaphase stage of chromosome of mitosis cell cycle (Fig. 6B). Concerning the wound's neighborhood areas, more epithelial layers have been reconstructed and packaged as a tight unit of functional epidermis (Fig. 5A-B). Outermost protective keratin portion was reconstructed, resulting as a thin layer at the wound area (Fig. 5B). Compared to the adjacent area, the connective tissue of upper dermis has resembled the regeneration process by developing well-defined loose connective tissue characteristic, including dermal papilla structures (Fig. 5A-B). At the wound area, the dermis similarly demonstrated the very well regeneration of newly formed fibroblasts and tightly interconnecting of regularly organized collagen bundles (Fig. 5C-D; 6E-F). The presentation of newly formed blood vessels was especially performed and developed throughout the dermis, defined by lots of sections of thicken-wall blood vessels with internal large cuboidal endothelial cells (Fig. 5D&F; 6C-D), which has not presented in the non-ozone treated group. According to relation with immune system, the majority of white blood cells were mostly lymphocytes and new wandering plasma cells, together with the decreased numbers of neutrophils (Fig. 6G-H). The portion of large abscess has almost disappeared, comparing to the non-treated condition. Interestingly, the clarify and dominant structure of defense mechanism, termed as foreign body giant cells, were presented and distributed over the dermal area (Fig. 5E; 6I).

### DISCUSSION

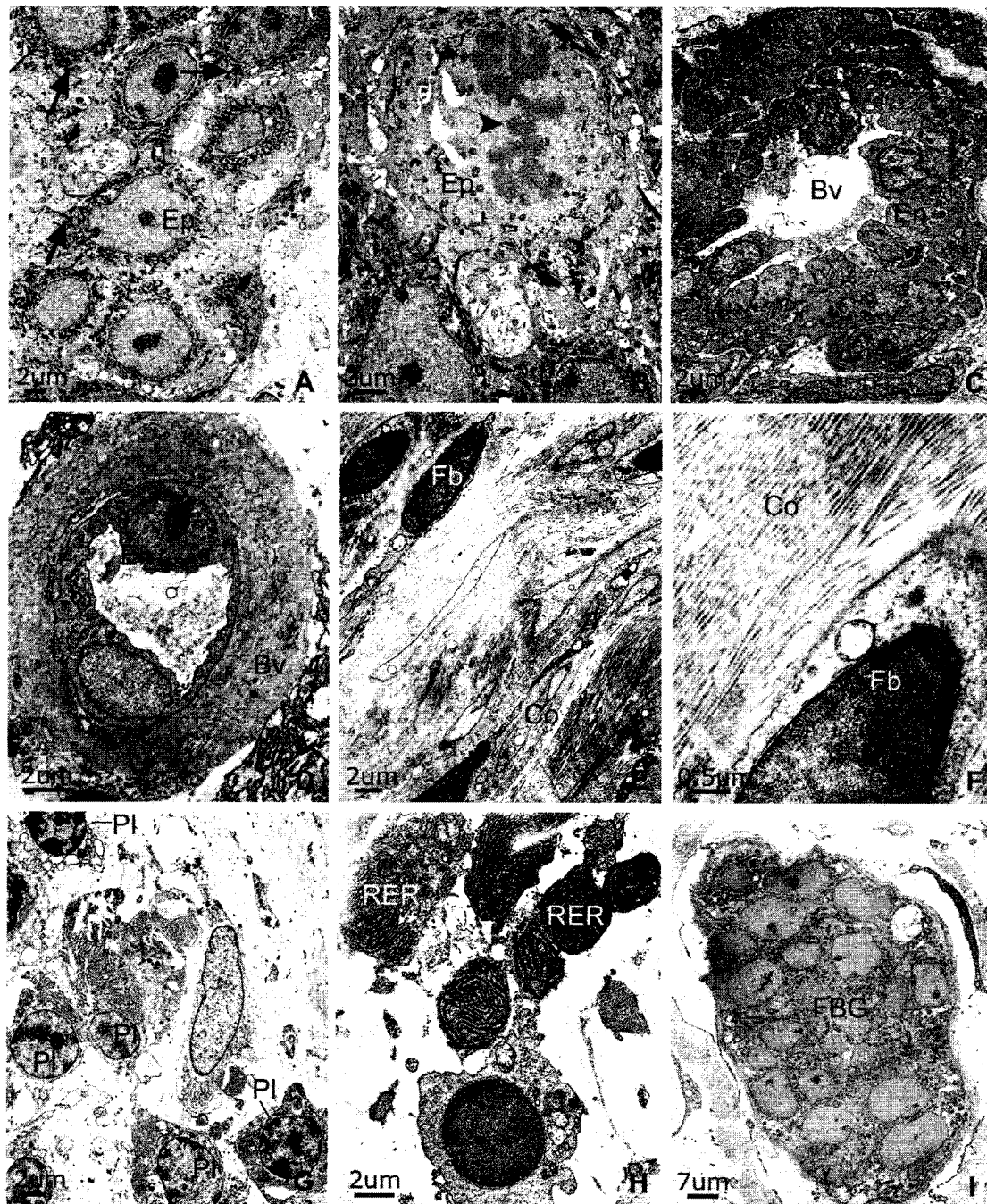
The study indicated that ozonated water therapy could enhance well-developed improvement of infected diabetic wound, including cell and tissue reorganization and bactericidal potential. For wound healing, there was a well-recovered keratin, corresponding with more newly regenerated epithelial cells growing and migrating in order to reconstitute the new layers of epidermis, including well-defined connective tissue through out the dermis. The newly recognized blood vessels might be related to the event of increased oxygen in the healing tissue (19). Furthermore, a charge modification in red blood cell membranes resulted in an improvement in membrane flexibility and a decrease in blood viscosity and resistance (11).

With regard to defensive response, untreated wound showed acute inflammation, revealing extensive abscesses, predominant neutrophils, enlarged lesions, and granulation tissues. In contrast, ozone-treated wound presented decreasing acute inflammatory process, correlating with lower numbers of neutrophils and lymphocytes and higher numbers of plasma cells, which generally participate in antibody secretion and chronic inflammation. Consequently, multinucleated giant cells in ozone treated wound might indicate the up-regulation of delay-typed hypersensitivity, which is a major of defense against a variety of pathogen, particularly infected microorganism in the diabetic wound. Generally, ozone has been extensively recognized as a very potent microbicidal agent for the inactivation of bacteria, fungi, and viruses (20-22). Therefore, ozone capability, together with the antibiotic treatment might involve in some mechanisms in order to demolish microorganism in the infected area. Nevertheless, ozone therapy has been used successfully in treatment of some clinical diseases, such as for ischemic disorders (23-26). With appropriate concentrations and method, ozone showed the application of protection against free radical damage of heart, prevention of renal and hepatic disorders (25-26), increasing of cellular anti-oxidant enzymes, eventually inhibiting the oxidative stress (10, 27-29). Recently, the effect of radiotherapy was improved in advanced tumors when ozone therapy was included as adjuvant in chemoradiotherapy schedules (24).





**Fig. 5.** Light micrograph of five-day infected wound in non-ozone treated skin. The well-organized characteristics of epidermis (Ep) and dermis (De), including outermost reformed keratin were demonstrated (5A-C). At wound area (5C-E), regeneration of newly epidermal layers was distinctly observed (5C: arrows) whereas dermis showed regularly organized collagen bundles (Co), lot of newly formed blood vessels (Bv), and multi-nucleated foreign body giant cells (FBG). Higher magnification of cuboidal endothelial cell (En) and thick wall of blood vessels was shown in 5F.



**Fig. 6.** TEM micrograph five-day infected wound in ozone treated skin. Well-defined repair characteristics of skin (6A-B) was demonstrated by newly healthy epidermal cells (Ep) with intercellular bridge (arrows) and meta-phase chromosomal stage of mitosis (arrowhead).Dermis (6C-I) showed regeneration process of young fibroblasts (Fb), organized collagen bundles (Co), newly formed blood vessels (Bv) with large endothelial cells(En), together with clusters of plasma cells (PI) with dominant rough endoplasmic reticular (RER). Presentation of foreign body giant cells (FBG) was generally observed.

In conclusion, external ozone therapy with appropriate controlled method may be applied as another alternative medicine to improve the quality of clinical treatment in diabetic infected wound. The application of ozone disaffection and therapeutic index might reduce microorganism severity and enhance the process of skin regeneration. However, the exact mechanism and potential of ozone efficacy in practical treatment should be further studied.

## ACKNOWLEDGEMENT

This study was supported by the Srinakharinwirot University and Ministry of University Affairs' Research Grant, 2002. We also appreciate Assistant Professor Nantana Kaewpila, MD. for her help and kindly support for the special pathological investigation

## REFERENCES

1. Komanapalli IR and Lau HS. Ozone-induced damage of *Escherichia coli* K-12. *Appl. Microbiol. Biotechnol.* 1996; 46:610-14.
2. Komanapalli IR. and Lau HS. Inactivation of bacteriophage  $\lambda$ , *Escherichia coli* and *Candida albicans* by ozone. *Appl. Microbiol. Biotechnol.* 1998; 49:766-9.
3. Thanomsab B, Anupunpisit V, Chanphetch S, et al. Effects of ozone treatment on cell growth and ultrastructural changes in bacteria. *J. Gen. Appl. Microbiol.* 2002; 48:193-9.
4. Masaoka T, Kubota Y, Namiuchi S, et al. Ozone decontamination of bio-clean rooms. *Appl. Environ. Microbiol.* 1982; 43:509-13.
5. Rice RG, Farquhar JW, Bollyky LJ. Reviews of the applications of ozone for increasing storage times of perishable foods. *Ozone Sci. Eng.* 1982; 4:147-63.
6. Sheldon BW and Brow AL. Efficacy of ozone as a disinfectant for poultry carcasses and chill water. *J. Food Sci.* 1986; 51:305-12.
7. Chen HC, Huang SH, Moody MW, et al. Bacteriocidal and mutagenic effects of ozone on shrimp (*Penaeus monodon*) meat. *J. Food Sci.* 1992; 57:923-7.
8. Glaze WH. Drinking water treatment with ozone. *Environ. Sci. Technol.* 1987; 21:224-30.
9. Wolfe RL, Stewart MH, Liang S, et al. Disinfection of model indicator organisms in a drinking water pilot plant by using peroxone. *Appl. Environ. Microbiol.* 1989; 55: 2230-41.
10. Hernandez F, Menendez S, Wong R. Decrease of blood cholesterol and stimulation of antioxidative response in cardiopathy patients treated with endovenous ozone therapy. *Free Radic. Biol. Med.* 1995; 19:115-9.
11. Verrazzo G, Coppola L, Luongo C, et al. Hyperbaric oxygen, oxygen-ozone therapy, and rheologic parameters of blood in patients with peripheral occlusive arterial disease. *Undersea Hyperb. Med.* 1995; 22: 17-22.
12. Rickard G, Richardson R, Jhonson T, et al. Ozone therapy for the treatment of dental caries. *Cochrane Database Syst. Rev.* 2004; 3:CD004153.
13. Jakab GJ, Spannake EW, Canning BJ, et al. The effects of ozone on immune function. *Environ. Health Perspect.* 1995; 103: 77-89.
14. Wolcott J, Zee Y, Osebold J. Exposure of ozone reduces influenza disease severity and alters distribution of influenza viral antigens in murine lungs. *Appl. Environ. Microbiol.* 1982; 44: 723-31.
15. Peden DB and Dailey L. Modulation of mast cell functions by in vitro ozone exposure. *Am. J. Physiol.* 1995; 268: 902-10.
16. Turcic J, Hancevic J, Antoljak T, et al. Effects of ozone on how well split-thickness skin grafts according to Thiersch take in war wounds. Results of prospective study. *Langenbecks Arch. Chir.* 1995; 380: 144-8.
17. Lipmann M. Health effects of tropospheric ozone. *Environ. Sci. Technol.* 1991; 25:1954-62.
19. Bocci V, Valacchi G, Corradeschi F, et al. Studies on the biological effect of ozone: Generation of reactive oxygen species (ROS) after exposure of human blood to ozone. *J. Biol. Regul. Homeost. Agents.* 1998; 12:67-75.
20. Boyce DS, Sproul OJ, Buck CE. The bentonite clay on ozone disinfection of bacteria and viruses in water. *Water. Res.* 1981; 15:759-67.
21. Cross JB, Currier RP, Yorraco DJ, et al. Killing of *Bacillus* spores by aqueous dissolved oxygen, ascorbic acid, and copper ions. *Appl. Environ. Microbiol.* 2002; 69:2245-52.
22. Cho M, Chung H, Yoon J. Disinfection of water containing natural organic matter by using ozone-initiated radical reactions. *Appl. Environ. Microbiol.* 2003; 69:2284-91.
23. Berson EL, Remulla JF, Rosner B, et al. Evaluation of patients with retinitis pigmentosa receiving electric stimulation, ozonated blood, and ocular surgery in Cuba. *Arch. Ophthalmol.* 1996; 114:560-3.
24. Clavo B, Perez JL, Lopez L, et al. Oxone therapy for tumor oxygenation: a pilot study. *Evid. Based Complement Alternat. Med.* 2004; 1:93-8.
25. Barber E, Menendez S, Leon OS, et al. Prevention of renal injury after induction of ozone tolerance in rat submitted to warm ischemia. *Mediators Inflamm.* 1999; 8:37-41.
26. Peralta C, Leon OS, Xaus C, et al. Protective effect of ozone treatment on the injury associated with hepatic ischemia reperfusion: antioxidant-prooxidant balance. *Free Radic. Res.* 1999; 31:191-6.
27. Leon OD, Menedaz S, Merino N, et al. Ozone oxidative preconditioning: a protection against cellular damage by free radicals. *Mediators Inflamm.* 1998; 7:289-94.

28. Lerner AR. and Eschenmoser A. *Ozone in Biology. Proc. Natl. Acad. Sci.* 2003;100: 3013-15.
29. Bocci V. *Does ozone therapy normalize the cellular redox balance? Implications for therapy of human immunodeficiency virus infection and several other diseases. Med Hypotheses.* 1996; 46:150-4.